



















Country	CET/CPD information	Audience	Competencies	MCQs
UK	<p>This article offers a choice of 1 non-interactive CET point (C-70428) or 1 interactive CET point (C-70430) (For instructions on how to complete the interaction see the end of this article.)</p> 	   	            	6
ROI	All articles are CPD accredited in the Republic of Ireland			6

Contact lens series - Part 5: Complications of contact lens wear: microbial and sterile infiltrative keratitis

by **Chris Steele**, BSc(Hons) FCOptom DCLP DipOC DipTp(IP) FBCLA

Outline:

In the penultimate part of this series, contact lens (CL)-related microbial keratitis (MK) management is discussed. This is a relatively rare but potentially sight-threatening condition. This article outlines how optometrists should always practise within their clinical competencies and refer if in doubt or in cases that do not respond to treatment.

Optometrists (particularly those who are IP qualified) can now treat a wide range of red eye conditions, many of which are associated with CL-related ocular complications. Being able to rapidly and accurately diagnose more severe, sight-threatening complications is vital so that urgent referral can be made for appropriate treatment to prevent vision loss. The importance of keeping complete patient records and fully complying with consent requirements from the General Optical Council (GOC) is also discussed.



About the author:

Chris Steele graduated from City University in 1988 and was a prizewinner in ocular disease and abnormality examinations. He qualified in July 1989 after his pre-registration year at the Royal East Sussex Hospital, Hastings. He is Consultant Optometrist, Head of Optometry at Sunderland Eye Infirmary (SEI) in Sunderland. Over the past 25 years he has developed a wide range of extended roles within his optometry team involving predominantly medical retina, cataract, glaucoma, anterior segment and paediatric caseloads. He has maintained his special interest in medical therapeutic contact lenses and still runs a specialist scleral lens tertiary referral service at SEI. He has also continued to undertake regular locum work in community optometric practice. He has authored over 70 publications re glaucoma, ocular therapeutics, medical retina, specialist medical contact lenses, refractive surgery and clinical risk management and has undertaken many presentations both nationally and internationally on these topics. He has authored two books, the first in the Eye Essentials series, *Diabetes and the Eye*, published by Elsevier in 2007. His latest reference textbook is entitled *Systemic and Ophthalmic Management of Diabetes Mellitus*, published by JayPee Medical Publishers. Chris has been a College examiner for pre-registration final exit examinations and postgraduate higher qualifications (diabetes and glaucoma) since 1996. He is currently a question writer and editor for the College of Optometrists Therapeutics Central Final Assessments in Independent Prescribing, as well as a co-editor for Specsavers' *Profile* journal. Chris was a member of the NICE Glaucoma Guideline Development Group from 2007 that produced the NICE glaucoma guidelines (CG85) published in 2009, and is still involved in the ongoing NICE periodic reviews of this glaucoma guideline as an appointed expert adviser. In the past 5 years he was also a member of the College of Optometrists Medical Retina Development Group that produced the new Medical Retina Higher Qualifications for optometrists.

Introduction

There are an estimated 140 million individuals who wear contact lenses (CLs) worldwide.¹ CL wear is generally thought of as a safe and effective way to correct refractive error; however, as discussed in Parts 2-4 of this series, adverse reactions may occur. Complications of CL wear are generally self-limiting on lens removal, with the exception of CL-related microbial keratitis (MK), a relatively rare but potentially sight-threatening condition (see below). Despite the significant developments in the CL market, with the increased use of frequent replacement and daily wear CLs, in combination with advances in CL technology, CL-related keratitis continues to be a serious problem. Less severe forms of CL-related keratitis and

inflammation are more commonly encountered than before these developments in CL technology. The appropriate management of these conditions by the CL practitioner will be discussed in this article.

With so many potential risks associated with CL wear and the number of options available, CL practitioners should always take the time to obtain informed consent from their patients. This is really important for a number of reasons:

- Patients will be better educated and are less likely to be dissatisfied with their CL wear as a result of unrealistic expectations.

- Permanent records of written consent comply with the GOC requirements for best practice in record keeping as well as providing evidence that patients have received all the appropriate information to enable them to give their informed consent.
- Furthermore, informed consent helps protect the CL practitioner against allegations of malpractice and negligence.

The importance of informed consent is discussed in some detail at the end of this article.

Microbial keratitis

The most significant complication of CL wear is MK, a microbial infection that causes sight-threatening corneal ulceration (Figure 1). In a landmark study in 1991, Dart et al. reported that CL wear accounted for 65% of all new cases of MK in the UK.² More recent studies from around the world have found similar estimates ranging from 52-63%.³⁻⁵ With current CL wear modalities, despite all the lens material technological advances and improved oxygen transmissibility, the reported incidence has remained effectively unchanged for daily and extended wear over the past 25 years.⁶⁻⁸ Epidemiological studies of contemporary CL wear have estimated the incidence of MK in daily wear at 3-5 per 10,000 lens wearers per year, with incidence varying according to wear modality.⁶ According to Stapleton and Carnt, the incidence rate for MK with overnight use of silicone hydrogel lenses is no different to that of hydrogel CLs (1 per 500 wearers per year).⁹ They also demonstrated that daily disposable CLs were not associated with a lower risk for MK than frequent replacement daily wear CLs.

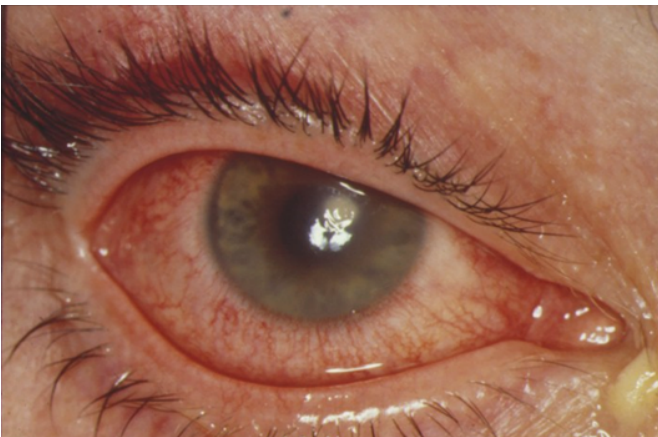

Figure 1: Microbial keratitis

Keratitis may present in many different forms. The definition of MK often used in the literature includes either a positive corneal culture or a corneal infiltrate and overlying epithelial defect with one or more of the following signs:

- Any part of the lesion within or overlapping the central 4 mm of the cornea
- Uveitis
- Pain

Moderate and severe MK associated with daily use of CLs has been found to be closely linked to instances involving contamination of CL storage cases (including inappropriate frequency of storage case replacement, hygiene, and solution type). Other factors include occasional overnight use of CLs, smoking, and socioeconomic class (discussed in Part 1 of this series).¹⁰

Generally, superficial keratitis does not result in corneal scarring, whereas deeper stromal keratitis does. Corneal infiltrates are a

common feature in keratitis of many different causes. Slit lamp biomicroscopy is essential to determine the presence of infiltrates, which are not usually visible to the naked eye. Corneal infiltrates consist of single or multiple discrete greyish white cell accumulations of mainly polymononuclear leukocytes (neutrophils) as well as lymphocytes and macrophages. These migrate from the limbus or tear fluid into the cornea. Infiltrate formation can occur as a response to local tissue damage and secondary chemotactic factors, or the presence of antigens and toxins, e.g. from a CL or an infective cause. Accurate clinical assessment of both symptoms and signs is very important and scraping the cornea for cultures makes the diagnosis much easier (see below). Important diagnostic factors include:

- Reported symptoms, e.g. pain, photophobia
- Size, location, depth, shape and colour of the lesion
- Corneal staining
- Any anterior chamber activity (with or without hypopyon)
- Conjunctival injection (circumferential in severe cases but more sectoral in less severe cases)

Corneal infiltrates associated with CL wear may present from a variety of causative factors. In CL wear, infiltrates are most often sterile (non-infectious), but may also be infectious. One study showed that infiltrates tend to occur in the superior cornea of patients wearing extended wear silicone hydrogel lenses, in the central cornea of patients wearing daily wear disposable lenses and in the peripheral cornea of patients wearing daily wear hydrogels (excluding daily disposables).¹¹ Infiltrates that appear near the limbus are generally less severe (Figure 2).

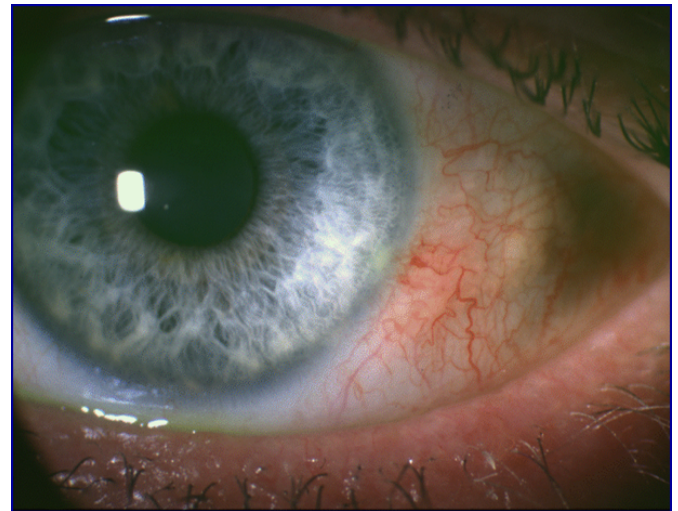

Figure 2: Peripheral corneal infiltrate with sectoral limbal injection

As mentioned above, the risk of infection (with infectious infiltrates) associated with daily disposable CLs is not significantly different to that of other daily use CLs. However, the rate of severe/moderate keratitis in daily disposable CLs is reportedly low compared with frequent replacement daily wear CLs, resulting in a relatively low risk of vision loss with this modality.¹² This is most likely explained by the fact that daily disposable CLs are not exposed to the same risk factors associated with hygiene procedures as frequent replacement daily wear CLs. The low rate of severe disease when daily disposable lenses are worn, on a strict daily disposable wear basis, would suggest this modality is the safest.¹³

Soft frequent replacement daily wear CLs are the most common type of lens associated with corneal ulcers. With these, the most common causative organism is *Pseudomonas aeruginosa*, followed by other Gram-negative bacteria and the protozoan *Acanthamoeba*.¹⁴ This finding is supported by a retrospective analysis of over 500 corneal

ulcers (223 of which were CL-related) treated at the Wills Eye Institute, Philadelphia USA, by Yildiz et al.¹⁵ Soft frequent replacement daily wear CLs were used in 68 (33.5%) of 223 cases. There was a history of overnight wear of CLs in more than half of the cases (121 of 223; 54.3%); of these, 21 (9.4%) were not approved for overnight wear.¹⁵

Keratitis treatment

The CL practitioner should be aware of the inadequacies of over-the-counter antibiotic eye drops, which have limitations for the treatment of anything other than relatively minor infections (Figure 3). Although gutte. chloramphenicol and occ. fusidic acid are now widely available for use in optometric practice, neither of these are effective against *P. aeruginosa*. Polyfax (a combination of polymyxin B and bacitracin) does, however, have some effectiveness against *P. aeruginosa* and is available for use and supply by additional supply optometrists and may be used and prescribed by independent prescribing (IP) optometrists. Where appropriate, the ointment should be used two to three times a day depending on the severity of the condition, with treatment being continued for at least two days after the eye has apparently fully recovered.

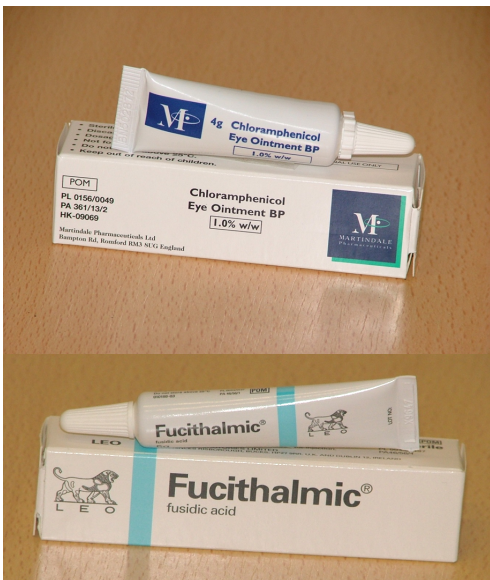

Figure 3: Over-the-counter antibiotics

The importance of discontinuing CL wear and discarding contaminated CLs and CL cases in scenarios involving CL-related infection cannot be overemphasised. It is recommended that wherever *Pseudomonas* infection is suspected, patients should be immediately referred to secondary care for treatment with third- and fourth-generation fluoroquinolones and other fortified antibiotics, if required (see below).¹⁶

Bacterial keratitis management

The initial management of bacterial keratitis should nearly always involve a corneal scrape to guide therapy, remove debris and improve antibiotic penetration. After explaining the procedure fully to the patient, a 20 gauge needle or surgical sterile blade is used to remove superficial debris from the ulcer, and then to scrape the edges and base (using a fresh needle/blade for each tissue sample removal). The collected material is spread onto glass slides for Gram and Giemsa staining and left to air dry. Additional scrapes should be taken for each chosen agar culture medium. These may include blood agar, chocolate agar and Sabouraud's agar. Covers should be

taped onto the plate to avoid evaporation. CLs themselves, as well as lens cases and solutions, should also be cultured. It can take from 24 hours to two weeks to obtain all results, particularly where fungi, *Acanthamoeba* or anaerobic organisms are involved.

Cycloplegia should be induced to help with pain control using homatropine 0.5% twice daily (b.d.), for example. In the UK, quinolone resistance is not a significant concern, so antibiotic treatment may start with a third- or fourth-generation quinolone, e.g. levofloxacin or moxifloxacin. Alternatively, dual therapy with fortified (hospital pharmacy manufactured) cephalosporin and aminoglycoside (e.g. gutte. cefuroxime 5% and gutte. gentamicin 1%) may be considered, depending on severity. These should be administered hourly overnight for the first night in severe cases; in less severe cases this may be omitted but continued hourly during the day for at least 5 days. If, for any reason, patients or their relatives are deemed unable to comply with the treatment regimen, then hospital admission is normally required.

Generally, patients should be reviewed after 2 days with microbiology culture findings. Depending on the results, it may be necessary to change treatment to something more specifically sensitive to the causative organism, but changes should be avoided unless absolutely clinically necessary. The patients should be reviewed again after 5 days. If responding well, antibiotic drops may be reduced to four times a day (q.d.s.). A steroid may also be considered at this stage (e.g. gutte. prednisolone 0.5%) to help reduce any inflammation, although this is not well supported by the evidence base.^{17,18} If there has been a poor response to treatment thus far, referral to a subspecialist is recommended to investigate for other unusual causes and undertake further investigations as necessary. These may include confocal microscopy, re-culturing and identification of microbial/fungal DNA using a laboratory technique called polymerase chain reaction (PCR). Antibiotic therapy should then be altered as appropriate.

Fungal keratitis

Although rare, ocular trauma and CL wear are associated with filamentous fungal infections, most commonly caused by *Aspergillus*, *Fusarium* or *Paecilomyces* spp. Fungal keratitis presents with a unilateral red eye, lacrimation, and reduced vision. Pain and photophobia are often mild in the early stages but may become severe relative to presenting clinical signs. The corneal surface may appear grey with a roughened, lustre texture (Figure 4). Quickly progressing feathery branching filaments may be observed on slit lamp biomicroscopy, but not always. Sometimes, an endothelial plaque is seen under the corneal lesion with satellite lesions around the periphery (Figure 5). Suppurative keratitis, anterior chamber hypopyon and raised intraocular pressure (IOP) may also be evident.

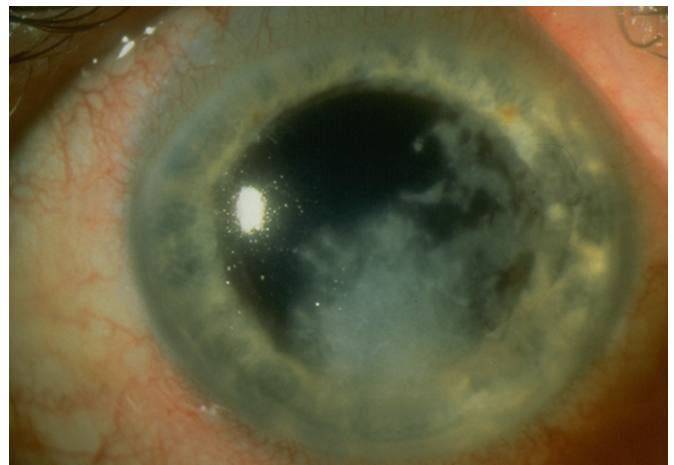

Figure 4: Fungal keratitis (Courtesy of Mr SJ Morgan)

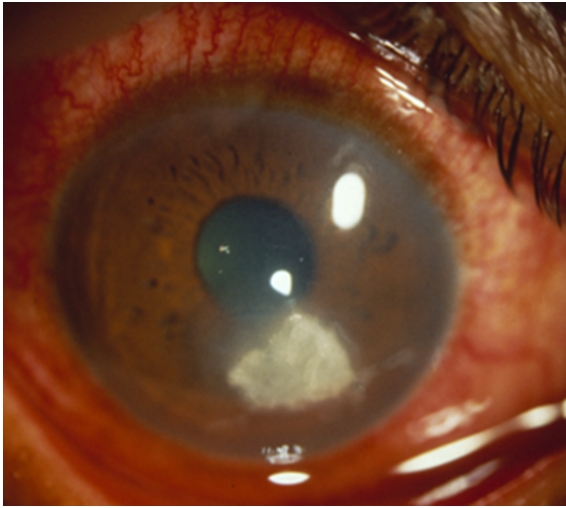


Figure 5: Endothelial plaque (Courtesy of Mr SJ Morgan)

Differential diagnosis includes herpes simplex virus, *Acanthamoeba* and atypical bacterial keratitis including *Nocardia* and *Mycobacterium*.¹⁹ Management of fungal keratitis is beyond the scope of an IP optometrist. It involves the use of gutte. natamycin 5% administered hourly day and night for several days and reduced as signs improve. Chlorhexidine 0.2% may also be necessary at this stage. If these prove ineffective, then other treatment options may include gutte. voriconazole 1% and gutte. amphotericin 0.15%. Cycloplegics should be used as necessary for pain relief and uveitis management to prevent posterior synechiae formation. Unfortunately, recurrence of fungal keratitis is quite common.

Microsporidium keratitis

Microsporidium keratitis is rare but may be seen in patients (including CL wearers) who have contracted their disease overseas, particularly following visits to Hong Kong, Singapore and other South-East Asian areas. The organism does not grow in culture and the diagnosis is confirmed by histological examination of an epithelial biopsy. In the majority of cases, the disease is limited to the epithelium where the appearance can mimic *Acanthamoeba* infection. Epithelial disease is managed by epithelial debridement and the use of a topical fluoroquinolone.²⁰

Acanthamoeba keratitis

Around 85% of all *Acanthamoeba* keratitis (AK) cases are related to CL wear. The causative organism, a ubiquitous, free-living protozoan, may be isolated from CLs and water (fresh, salt, tap and swimming pools). *Acanthamoebae* can exist in two forms²¹:

- A motile, feeding and replicating trophozoite form, commonly found in water and easily destroyed
- A dormant form with cyst formation which is highly resistant to disinfection and can survive for long periods in hostile environments

If questioned carefully, the patient history will often include reports of overuse of CLs, poor cleaning regimens (particularly solution topping up and handling lenses with wet hands), swimming (without goggles) and showering with CLs in, or unintended contact with stagnant water in agricultural areas, for example.²² Signs of *Acanthamoeba* are highly variable, but the infection is usually unilateral. Initially, the cornea may exhibit signs of superficial punctate keratitis, reduced corneal sensation, and pseudo-dendritic lesions. Later, peri-neural infiltrates may form peripherally or even centrally. Stromal infiltrates may well be evident and become quickly widespread. Characteristic ring infiltrates may form in the later

stages, but are not seen in the first few weeks (Figure 6). Often the initial stages are misdiagnosed as herpes simplex keratitis. Other differential diagnoses include fungal and bacterial keratitis.

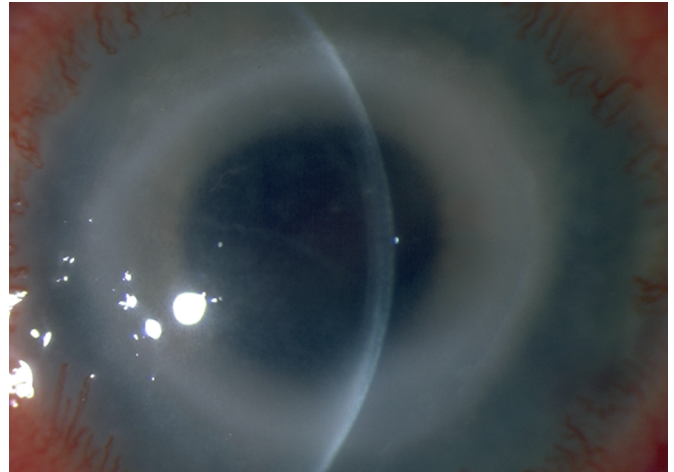


Figure 6: *Acanthamoeba* ring infiltrates (courtesy of Mr SJ Morgan)

Treatment of *Acanthamoeba* infection can be very challenging. This is partly because *Acanthamoeba* cysts are very resistant to treatment. Treatment usually includes ceasing any previously prescribed steroids and starting the patient on gutte. polyhexamethylene biguanide (PHMB) 0.02% or gutte. chlorhexidine 0.02% hourly. If necessary, either gutte. propamidine 0.1% or gutte. hexamidine 0.1% hourly may be added. Other antibacterials or antifungals may also be required. Steroid use is complex and should be used prudently by experienced specialists only. Analgesics typically include non-steroidal anti-inflammatory drugs, e.g. flurbiprofen 50-100mg t.d.s. Co-codamol and codeine are other alternatives. Continuous treatment may be necessary for weeks or months. Penetrating keratoplasty may even be necessary if corneal irregularity, thinning and/or scarring is severe following complete control of the infection.

There are no formal guidelines or standards of care for the treatment of AK.²¹ A recent systematic Cochrane review reported data from a randomised control trial which compared two topical biguanides for the treatment of AK (chlorhexidine 0.02% and PHMB 0.02%).²³ Resolution of infection (defined as control of ocular inflammation, relief of pain and photosensitivity, and recovery of vision) was 86% in the chlorhexidine group compared with 78% in the PHMB group. However, this review concluded there is insufficient evidence to evaluate the relative effectiveness and safety of medical therapy for the treatment of AK.²³ AK is classified as requiring emergency (same day) referral to an ophthalmologist without intervention. AK management should not be attempted in community optometric practice, even by IP optometrists.²¹

Less serious CL-related keratitis and inflammation

In CL practice, it is important to be able to distinguish between relatively benign conditions that may be managed by the optometrist from the less common, but potentially sight-threatening, MK, AK and fungal keratitis described above. The various relatively benign types of keratitis can be summarised as follows:

- CL-induced peripheral ulcer (CLPU)
- CL acute red eye (CLARE)
- Infiltrative keratitis (IK)
- Asymptomatic infiltrative keratitis (AIK)
- Asymptomatic infiltrates (AI)

Other causes of infiltrates include adenoviral conjunctivitis and atopic/ vernal conjunctivitis (discussed in Part 2 of this series). In this article, consideration is given to those conditions where the optometrist or CL practitioner may be able to manage the condition themselves.

Contact lens-associated peripheral ulcer (CLPU)

CLPU (sometimes referred to as CL-associated culture negative peripheral ulcer [CNPU], or culture sterile ulcer) usually gives rise to unilateral single, or sometimes multiple, whitish/grey focal anterior stromal infiltrates in the periphery or mid-periphery of the cornea (Figure 7). CLPUs can occur at any position in the peripheral and mid-peripheral cornea. They are often seen in extended and continuous wear CL patients, but may also be seen with daily wear CLs. CLPUs are caused by an inflammatory reaction to toxins released by Gram-positive bacteria (e.g. *Staphylococcus aureus* and *S. epidermidis*) that colonise the CL surfaces (and are also responsible for causing blepharitis). The resultant round infiltrates can range in size from 0.1 mm to 2.0 mm in diameter and on acute presentation will involve a full-thickness loss of epithelium with resultant fluorescein staining. They rarely extend beyond the anterior stroma when viewed in cross section with a slit lamp biomicroscope. The eye will appear red with sector limbal injection if a focal infiltrate is more peripheral, but the anterior chamber will be quiet without flare or cells.²⁴ Symptoms vary from none at all to moderate foreign-body sensation, redness, epiphora and mild to moderate photophobia.

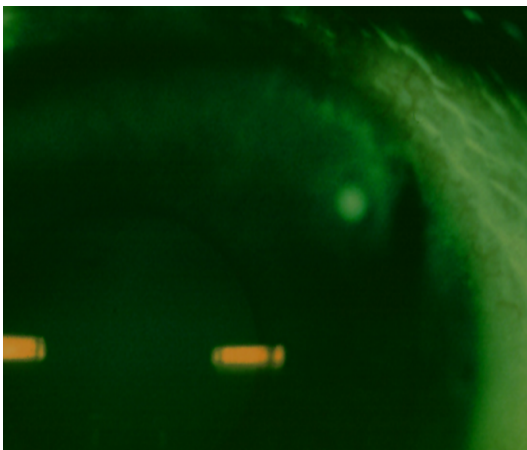

Figure 7: Contact lens-associated peripheral ulcer

The differential diagnosis for CLPU includes:

- Early MK
- Marginal keratitis
- Corneal phlyctenulosis
- Other peripheral corneal lesions

The signs which distinguish sight-threatening keratitis, which requires urgent referral, from CLPU include:

- Increasing severity of signs and symptoms after lens wear has been discontinued
- Irregular infiltrates with raised edges and sometimes associated satellite lesions
- Mucopurulent discharge, adherent to the lesion (particularly in *Pseudomonas* infection)
- Lid oedema
- Severe diffuse bulbar and limbal hyperaemia
- Marked anterior chamber reaction (flare and cells, possible hypopyon)

Unlike MK, CLPUs have milder symptoms and quickly resolve with lens discontinuation, in the absence of therapeutic intervention. As the clinical presentation of CLPU and early MK can be so similar, it is usual to treat CLPU cautiously in the Hospital Eye Service (HES). This involves discontinuing CL wear immediately, but also treating with topical fluoroquinolone monotherapy, e.g. levofloxacin. Provided the clinical signs and symptoms are relatively mild (usually with no or very mild anterior chamber activity, or lid oedema), the patient is instructed to instil their medication at home and are reviewed again within 2-3 days. In a community optometric setting, practitioners should recognise their limitations and, where necessary, seek further advice or refer the patient elsewhere.

In accordance with the published College of Optometrists Clinical Guidelines, it is really important that the community optometrist is able to differentiate between CLPU and actual sight-threatening corneal infections. Cessation of CL wear for at least 48 hours usually results in complete resolution of both signs and symptoms of this condition. All patients should be reminded of the importance of CL hygiene regimens, particularly hand washing before touching their CLs, appropriate (frequent) lens case replacement and not wearing CLs overnight.²⁵

Marginal keratitis

While not technically a complication of CL wear, a brief discussion of marginal keratitis is included here for differential diagnostic purposes. Although marginal keratitis is a self-limiting condition, it is common for optometrists to give pharmacological treatment with a view to relieving symptoms and shortening the clinical course. However, this practice is not supported by evidence from clinical trials.²⁶

Marginal ulcers (marginal keratitis), caused by peripheral corneal hypersensitivity to staphylococcal exotoxins, are typically oval in shape and located at the 2, 4, 8 and 10 o'clock positions and run parallel to the limbus (Figure 8). Symptoms associated with this condition include:

- Ocular discomfort increasing to pain
- Lacrimation
- Red eye
- Photophobia

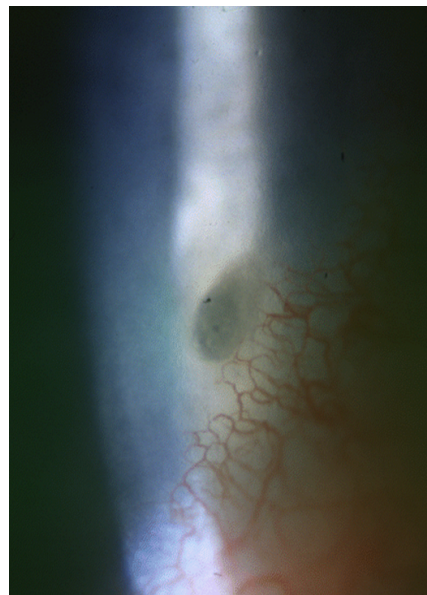


Figure 8: Marginal keratitis

With regards to the clinical signs, there is usually a clear gap between the infiltrate and limbus, but this can be spanned by blood vessels. Occasionally, there is no clear interval, as infiltrates are seen to stream from the limbal vasculature to the focal infiltrate. In these cases, treatment of the underlying lid condition should be addressed. Sometimes it is necessary for the community optometrist or CL optician to refer for topical steroid treatment (e.g. gutte. fluomethalone [FML], gutte. prednisolone 0.5% q.d.s.) and lid hygiene, followed by topical antibiotic ointment to the lid margin if necessary using oc. Fucithalmic b.d., for example. This may be treated independently by IP-qualified optometrists. Where steroids are prescribed, IOP should always be recorded prior to commencing treatment so that appropriate action can be taken if the IOP is found to be subsequently raised due to steroid use. Treatment should then be tapered according to response. Beware that cases associated with ocular rosacea sometimes may progress to perforation.

Practitioners should, however, recognise their limitations and, where necessary, seek further advice or refer the patient elsewhere. According to College of Optometrists, marginal keratitis is classified as a B3 condition, therefore, allowing optometric management to resolution. However, in persistent or recurrent cases HES referral to an ophthalmologist is recommended.²⁶

Other causes of ulceration of the peripheral cornea include:

- CL-associated MK
- CL-associated corneal infiltrate
- Rosacea keratitis
- Mooren's ulcer
- Peripheral keratitis associated with rheumatoid arthritis or other systemic collagen vascular disease
- Corneal phlyctenulosis
- Terrien's marginal degeneration
- Marginal herpes simplex keratitis

Contact lens acute red eye (CLARE)

This is a non-ulcerative sterile keratitis associated with colonisation of Gram-negative bacteria on CLs.²⁷ Typically, the patient (mainly wearing continuous or extended wear lenses or sometimes poorly fitting immobile lenses of any type) wakes up in the early morning with uniocular discomfort or pain, photophobia, watery discharge, bulbar and limbal hyperaemia. Slit lamp biomicroscopy examination will reveal:

- Subepithelial to anterior stromal infiltrates in the periphery of the cornea distributed either focally or diffusely, with a clear space between them and the limbus
- Reduced vision will occur if infiltrates develop in the central cornea but otherwise vision remains unaffected
- No staining or ulceration
- Pronounced circumlimbal injection
- Occasionally, in severe cases, flare and keratic precipitates will be involved, but this is not usual

It is vitally important to differentiate CLARE from MK, which is potentially blinding. Therefore, if there is any doubt about the diagnosis, the patient should always be referred.

As CLARE is non-ulcerative and non-infectious, it will subside with the removal of CLs. Temporary CL discontinuation, along with ocular lubrication, should facilitate the reduction of signs and symptoms.

If in any doubt, then a referral for fluoroquinolone monotherapy should be made. Re-assessment of CL fit should be undertaken in cases where tight-fitting lenses are the underlying cause. Switching to daily wear monthlies or daily disposables in recurrent cases is also recommended.

Asymptomatic infiltrates

These are usually small infiltrates that can occur in both CL and non-CL wearers and which are thought to be caused by environmental antigens (Figure 9). They are completely asymptomatic with no accompanying epithelial defect and do not require any treatment.

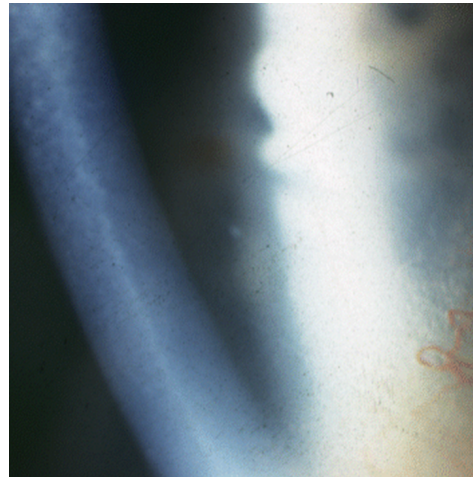

Figure 9: Asymptomatic infiltrate

Who can fit contact lenses in the UK?

It is important that all CL patients have their CLs fitted and regular aftercare provided by those properly qualified to do so. CL fitting is defined as assessing patient suitability and, where appropriate, providing one or more CLs for use during a trial period. The Opticians Act (1989) states that only registered medical practitioners, optometrists and dispensing opticians (with suitable qualifications) may fit a CL; there is a special exemption for supervised students (medical and optical) in training. This means it is actually a criminal offence for anyone unregistered to fit CLs, with potential conviction and large penalty fines impossible. This is important to remember with a growing number of patients now seeking CL supplies through the internet, as discussed in Part 1 of this series.

The importance of consent in CL practice

Before a healthcare professional examines or treats any patient, consent must be sought. In many instances, just verbally agreeing to a specified course of action is sufficient, or consent may be implied by their behaviour, such as resting their chin on the chin rest when you ask them to during a CL check-up, for example. Sometimes, a written record of a patient's decision is also highly desirable. Even though consent forms are very important and used extensively in secondary care, they are comparatively frequently overlooked or underused in optometric community practice. In relation to CL wear, it is recommended that a CL practitioner must discuss, at the very least, the following before a patient can give a valid informed consent:

- Diagnosis
- The purpose and benefits of suitable CL types
- The potential risks of complications, consequences and side effects related to CL wear. This should obviously include risks with serious consequences (such as the risk of AK due to poor lens hygiene and cleaning regimens). Less common risks should also be included, not only to minimise the possibility of allegations of carelessness and negligence, but also to ensure that patients have realistic expectations about how successful CL wear will be for them.
- Practicable alternative options to meet the needs of the patient
- Likelihood of success with various CL types and modalities
- Prognosis in the absence of treatment. This is very important in therapeutic (bandage) CL scenarios
- Patients should never wear CLs that do not conform to the manufacturer's wearing schedule guidelines, unless there are exceptional circumstances, such as might occur within the HES

The above is particularly important to discuss with patients wishing to wear CLs under certain potentially higher risk modalities of lens wear, in particular extended wear or orthokeratology involving overnight wear of rigid gas permeable CLs. Under these circumstances, a permanent record of the written consent form is always recommended. It is noteworthy that patients can and do change their minds about what treatment or CL modalities they wish to pursue - even after signing a consent form!

According to the General Optical Council's (GOC) Standards of Practice for Optometrists and Dispensing Opticians (2016)²⁸ it is essential to: *"obtain valid consent before examining a patient, providing treatment (this includes CL wear) or involving patients in teaching and research activities. For consent to be valid it must be given:*

3.1.1 *Voluntarily.*

3.1.2 *By the patient or someone authorised to act on the patient's behalf.*

3.1.3 *By a person with the capacity to consent.*

3.1.4 *By an appropriately informed person. Informed means explaining what you are going to do and ensuring that patients are aware of any risks and options in terms of examination, treatment, sale or supply of optical appliances or research they are participating in. This includes the right of the patient to refuse treatment or have a chaperone or interpreter present.*

3.2 *Be aware of your legal obligations in relation to consent, including the differences in the provision of consent for children, young people (see below) and vulnerable adults. When working in a nation of the UK other than where you normally practise, be aware of any differences in consent law and apply these to your practice.*

3.3 *Ensure that the patient's consent remains valid at each stage of the examination or treatment and during any research in which they are participating".*

There is no legal reason to prevent optometrists and CL opticians from fitting CLs for children, but from a clinical perspective, professional judgement regarding the clinician's own capabilities as well as the suitability of the child to be fitted with CLs must be carefully considered.

Healthcare professionals should also be clear about the legal age of children who may sign a consent form. This is particularly so for children wishing to wear CLs. By 16 years of age a child is considered to have reached the "age of majority" in relation to determining their own healthcare needs, as set out in section 8 of the Family Law Reform Act 1969 in England and Wales. Therefore, they can

legally consent to treatment or examination without their parents/guardian being informed. For children (often referred to as minors) less than 16 years, the parents should normally be involved in the decision-making process and decisions will be made in the child's best interests after assessing the potential risks and benefits of CL wear, for example. It is usually best practice to involve both the child and parent in the decision-making process at the consent stage prior to fitting CLs, especially with respect to 14/15 year olds, approaching their 16th birthday (and therefore age of majority). It is suggested that a 14-15 year old should be asked to sign the consent form in addition to the parent/guardian for good record keeping and documentary evidence, although there is no legal requirement for this to be undertaken.

It is feasible that a 15 year old may present with a valid spectacle prescription, wishing to try CLs without their parents' knowledge. In such a scenario, it is important to remember that some children under the age of 16 years may be considered "Gillick competent" and/or that they meet the "Fraser guidelines". Whether or not a child is capable of giving the necessary consent will depend on the child's maturity and understanding and the nature of the consent required. The child must be capable of making a reasonable assessment of the advantages and disadvantages of the treatment (or CL wear) proposed, so the consent, if given, can be properly and fairly described as true consent without parental involvement.²⁹ The practitioner, therefore, has to decide whether any such young person is in fact "Gillick competent", i.e. do they have the capacity and understanding to take decisions about their own eye care management, specifically the risks and responsibilities surrounding CL wear? Another important consideration is of course whether a 15 year old, presenting without their parents' knowledge will be able to meet the financial costs of CL wear.

The "Fraser guidelines" refer to the guidelines set out by Lord Fraser in his judgment of the Gillick case in the House of Lords (1985), which apply specifically to contraceptive advice, but may equally apply (although unlikely) to minors wearing CLs. Further discussion of these guidelines is beyond the scope of this article.³⁰ It is suggested that in most situations in optometric practice, the healthcare professional should try to persuade the child to inform the parents or to allow the practitioner to do so.

It is also important to ensure that full clinical records are kept every time there is a significant change to the CL wearing modality, or where new CLs with altered parameters are supplied. In order to avoid inadequate record-keeping, the conventional CL record forms may need to be modified or supplemented with checklists of essential assessments undertaken at each consultation, as evidence of appropriate management and care in case of a formal complaint against the clinician. Full and complete patient clinical records, including consent forms where appropriate, are essential in helping to protect the healthcare professional should a legal case arise.

Finally, on the issue of consent, it is important that the patient is kept adequately informed, and given a chance to ask questions about their CL care on a regular basis and any foreseeable risks. Failure to do so may expose the clinician to allegations of breach of duty and carelessness, which may lead to charges of clinical negligence if the patient suffers harm, e.g. corneal ulcer resulting in permanently reduced visual acuity. This is paramount when caring for extended wear CL patients and those undergoing orthokeratology treatment. The CL healthcare professional, therefore, has a duty to provide "reasonable" aftercare, which includes regular monitoring of the patient's CL-related clinical status and updating information as appropriate to ensure that the best interests of the patient are maintained at all times.

Consequently, it has been recommended that patients are given an emergency contact number, especially as CL wear usually takes place after normal office hours. There is no legal obligation

for practitioners to offer out of hours care services, but it is recommended by the College of Optometrists that instructions are provided for such situations, particularly if patients wear CLs on a continuous wear basis. This may simply be advice to attend the local eye casualty department.

In summary:

- It is important for CL practitioners to provide adequate information to the patients before (e.g. information leaflets and consent forms) and after commencing treatment or CL wear (education materials and advice).^{31,32} Information to the patient must be balanced and reasons given for any particular course of action or CL wear modality recommended. It is always helpful to ascertain what information the patient wants, as well as telling them what you think they need to know. All relevant information to the patient must be given, otherwise this may result in allegations of a breach of duty of care, leading to claims of negligence if the patient suffers harm as a result of the treatment. It is best practice not to withhold any information necessary for the patient to make a decision, unless the patient specifically asks not to have the information. The amount of information required varies considerably from one patient to another and sound clinical judgment is required to decide the correct balance! If important information is withheld from the patient, the specific reasons for doing so must be recorded in the patient's clinic notes.
- The rights of patients should be respected at all times and they should be fully involved in decisions about their care. If the patient has the capacity to consent, the clinician must obtain their consent before a physical (or eye) examination, starting treatment or helping them with their eye care, for example putting in drops or even inserting CLs.³³
- Consent must be obtained from patients who have capacity before starting any treatment or CL wear. Gaining consent from a patient is not a "one-off" event but part of an ongoing process between the clinician and the patient. Remember - a patient who is capable of giving consent may retract it at any time.
- Making decisions about treatment for patients who lack capacity is governed in England and Wales by the Mental Capacity Act 2005,³⁴ in Scotland by the Adults with Incapacity (Scotland) Act 2000 and in Northern Ireland by common law. So the legal framework for treating children and young people who lack the capacity to consent differs across the UK.
- Fitting CLs to patients who lack capacity however is most unlikely in primary optometric practice, but is at least theoretically possible.
- Patients over the age of 16 are presumed to have capacity to consent.
- Children and young people (aged 16-17) should wherever possible be involved in discussions about their treatment or CL wear regimen.
- Wherever possible always encourage children and young people to involve their parents in decision-making, particularly so with CL wear.
- Finally, the healthcare professional (in this case optometrist or CL optician) is responsible for ensuring the patient has given valid consent. This may be delegated to another person but only if the delegated person is suitably trained, qualified and possesses adequate knowledge of the proposed examination, treatment or CL wear modality to fully understand the risks involved, and competent in providing clear and accurate information in response to the patient's questions. Patients should never be pressured into accepting the healthcare professional's recommendations.

Conclusions

Optometrists (particularly those who are IP qualified) can now treat a wide range of red eye conditions, many of which are associated with CL-related ocular complications. A rapid and accurate diagnosis of more severe, sight-threatening complications is vital so that urgent referral can be made for appropriate treatment to prevent vision loss. Optometrists should always practise within their clinical competencies and refer if in doubt or in cases that do not respond to treatment. Full use should be made of The College of Optometrist Clinical Management Guidelines.³⁵

Printed information and informed consent forms are advisable when fitting suitable patients with CLs. It is vital to be aware and disclose all the foreseeable risks associated with CL wear associated with any particular modality. This particularly includes highlighting the small but potentially serious risk of corneal infection (especially MK).

When fitting children, the parents/guardians should be informed of their own responsibilities and the need for strong parental support and monitoring of compliance should be stressed.

Always keep patients fully informed about new products and opportunities. Do not let them hear about a new "wonder CL" that may be suitable (and perhaps better) for them from a third party. Always provide written (or web-based resources) to back up any advice given verbally in the practice and keep clear, accurate records of all advice given regarding CL wearing schedules, care solutions, etc. It is also important to remember to give the patient a new CL specification at every review appointment. Finally, endeavour to educate CL patients about the importance of CL review appointments and how they are vital to avoiding potential complications. Obtaining CLs from internet sources without appropriate supervision carries significant risks for things to go wrong, with potentially sight-threatening consequences.

References

1. Stapleton F, Keay L, Jalbert I, Cole N. The epidemiology of contact lens related infiltrates. *Optom Vis Sci.* 2007;84:257-72.
2. Dart JKG, Stapleton F, Minassian D. Contact lenses and other risk factors in microbial keratitis. *Lancet.* 1991;338:650-4.
3. Van der Meulen IJ, Van Rooij J, Nieuwendaal CP et al. Age-related risk factors, culture outcomes, and prognosis in patients admitted with infectious keratitis to two Dutch tertiary referral centers. *Cornea.* 2008;27:539-44.
4. Fong CF, Tseng CH, Hu FR et al. Clinical characteristics of microbial keratitis in a university hospital in Taiwan. *Am J Ophthalmol.* 2004;137:329-36.
5. Toshiya H, Kogure N, Inoue N, Murakami A. Trends in microbial keratitis in Japan. *Eye Contact Lens.* 2007;33:70-3.
6. Stapleton F, Keay L, Edwards K et al. The incidence of contact lens-related microbial keratitis in Australia. *Ophthalmology.* 2008;115:1655-62.
7. Stapleton F, Naduvilath T, Keay LJ et al. Risk factors for microbial keratitis in daily disposable contact lens wear. *Invest Ophthalmol Vis Sci.* 2010;51:1305.
8. Cheng K, Leung D, Hoekman H et al. Incidence of contact lens-associated microbial keratitis and its related morbidity. *Lancet.* 1999;354:181-4.
9. Stapleton F, Carnit N. Contact lens-related microbial keratitis: how have epidemiology and genetics helped us with pathogenesis and prophylaxis. *Eye (Lond).* 2012;26:185-93.
10. Stapleton F, Edwards K, Keay L et al. Risk factors for moderate and severe microbial keratitis in daily wear contact lens users. *Ophthalmology.* 2012;119:1516-21.
11. Efron N, Morgan PB. Rethinking contact lens associated keratitis. *Clin Exp Optom.* 2006;89:280-98.
12. Stapleton F, Keay L, Jalbart I et al. The epidemiology of contact lens related infiltrates. *Optometry and Vision Science.* 2008;84:257-72.
13. Radford CF, Minassian DC, Dart JK. Disposable contact lens use as a risk factor for microbial keratitis. *Br J Ophthalmol.* 1998;82:1272-5.
14. Mah-Sadorra JH, Yavuz SG, Najjer DM et al. Trends in contact lens related corneal ulcers. *Cornea.* 2005;24:51-8.
15. Yildiz EH, Airiani S, Hammersmith KM, et al. Trends in contact lens-related corneal ulcers at a tertiary referral center. *Cornea.* 2012;31:1097-102.
16. <https://www.college-optometrists.org/guidance/clinical-management-guidelines/microbial-keratitis-bacterial-fungal-.html> (accessed 26/4/17)
17. Herretes S, Wang X, Reyes JM. Topical corticosteroids as adjunctive therapy for bacterial keratitis. *Cochrane Database Syst Rev.* 2014;10:CD005430
18. McDonald EM, Ram FS, Patel DV, McGhee CN. Topical antibiotics for the management of bacterial keratitis: an evidence-based review of high quality randomised controlled trials. *Br J Ophthalmol.* 2014;98:1470-7
19. Moorfields Manual of Ophthalmology. Second Edition. 2014 pp191. JP Medical Limited, London.
20. The Royal College of Ophthalmologists Focus: microbial keratitis. <https://www.rcophth.ac.uk/wp-content/uploads/2014/08/Focus-Autumn-2013.pdf> (accessed 26/4/17)

21. <https://www.college-optometrists.org/guidance/clinical-management-guidelines/microbial-keratitis-acanthamoeba-sp-.html> (accessed 26/4/17)

22. Carnt N, Stapleton F. Strategies for the prevention of contact lens-related *Acanthamoeba* keratitis: a review. *Ophthalmic Physiol Opt.* 2016;36:77-92.

23. Alkharashi M, Lindsley K, Law HA, Sikder S. Medical interventions for *Acanthamoeba* keratitis. *Cochrane Database Syst Rev.* 2015;CD010792 (accessed 26/4/17).

24. Wu P, Stapleton F, Wilcox M. The causes of and cures for contact lens-induced peripheral ulcer. *Eye & Contact Lens: Science & Clinical Practice.* 2003;29:563-66.

25. <https://www.college-optometrists.org/guidance/clinical-management-guidelines/keratitis-cl-associated-infiltrative.html> (accessed 26/4/17)

26. <https://www.college-optometrists.org/guidance/clinical-management-guidelines/keratitis-marginal-.html> (accessed 26/4/17)

27. Holden B, Hood D, Grant T et al. Gram-negative bacteria can induce contact lens related acute red eye (CLARE) responses. *CLAO J.* 2006;22:47-52.

28. https://www.optical.org/en/Standards/Standards_for_optometrists_dispensing_opticians.cfm (accessed 26/4/17)

29. Gillick v West Norfolk and Wisbech Area Health Authority and Department of Health and Social Security [1984] Q.B. 581.

30. Wheeler, R. Gillick or Fraser? A plea for consistency over competence in children: Gillick and Fraser are not interchangeable. *British Medical Journal.* 2006;332:807.

31. https://www.bcla.org.uk/Public/Member_Resources/Professional_Resources/Do_s_Dont_s_Factsheet/Public/Member_Resources/Do_s_Dont_s_Factsheet_of_Contact_Lens_Care.aspx?hkey=5eb42bba-bae4-408a-8c2c-330cfa5608fb (accessed 26/4/17)

32. https://bcla.org.uk/Public/Member_Resources/Professional_Resources/Factsheets/Public/Member_Resources/Factsheets.aspx?hkey=fc6a2bd6-5f75-4ac8-b16f-9899d6a1c5cb&WebsiteKey=cfa0aa8b-7f48-4d52-8deb-0eeeab6928d8 (accessed 26/4/17)

33. Department of Health in England (2009) Reference guide to consent for examination or treatment second edition https://www.gov.uk/government/uploads/system/uploads/attachment_data/file/138296/dh_103653_1_.pdf (accessed 26/4/17)

34. Mental capacity act 2005. https://www.gov.uk/government/uploads/system/uploads/attachment_data/file/497253/Mental-capacity-act-code-of-practice.pdf (accessed 26/4/17)

35. <https://www.college-optometrists.org/guidance/clinical-management-guidelines.html> (accessed 26/4/17)

GOC's Enhanced CET Scheme

CET and CPD regulators require practitioners to reflect on their learning. Additional activities are required to gain CET for distance learning.

Log into your CET dashboard via iLearn. On the menu you reach you can choose either interactive or non-interactive CET for this unit of learning. If you choose 'non-interactive', you have to pass (>60%) a six-question multiple-choice quiz. If you choose 'interactive', you must pass the MCQ quiz and complete a further 30-minute discussion with a colleague, and upload a short summary of your discussion and reflections within 30 days. Note you must complete both tasks before your CET can be awarded. If you want the CET counted within a calendar year, make sure you submit the online record of discussion and remind your colleague to verify it online at least 2 weeks before the end of the year.

Further instructions for interactive learning are as follows:

The following steps must be completed within 30 days of completing the MCQ quiz:

1. Discuss the interactive questions below with a registered colleague. Note if you are an optometrist, the colleague must also be an optometrist. If you are a dispensing optician, the colleague may be a dispensing optician, a contact lens optician or an optometrist. The discussion should be in a quiet environment where you are not interrupted for at least 30 minutes. Discuss the set questions and record a summary of the output of your discussion. Please ensure to create a paper copy of your record. Sign and date the document and keep it safely stored in case your CET is audited in future by the GOC.
2. In the event of an audit, we need to be able to show the GOC that the interaction has taken place in accordance with the instructions. Therefore, before you can be given points for this activity you must, within 30 days, record your answers to the set questions in the online Discussion Record and Reflection form (link provided on iLearn).
3. You will be asked for the GOC number, name and email address of the colleague who has completed the interaction with you, so please have those ready. Your colleague will be contacted by email (so please make sure you enter their correct email address) and will be sent a link to verify the interaction took place.
4. You can only be awarded interactive CET points if these steps are completed within 30 days.

The learning objectives for this article are:

For optometrists

- 2.3.1 Optometrists will have an enhanced understanding of how to comply with requirements for consent to contact lens fitting, treatment or referral of corneal problems associated with contact lens wear
- 3.1.2 Optometrists will have an enhanced understanding of use of slit lamp for differential diagnosis of contact lens-induced peripheral ulcer and different forms of microbial keratitis
- 5.2.1 Optometrists will have an enhanced understanding of the management of corneal conditions associated with contact lens wear, which do not require urgent referral
- 6.1.3 Optometrists will have an understanding of the investigation and assessment of corneal sterile ulcers and different forms of microbial keratitis

For therapeutic optometrists

- 1.1.1 Therapeutic optometrists will have an enhanced understanding of the assessment of the patient and differential diagnosis of contact lens-induced peripheral ulcer and different forms of microbial keratitis
- 2.1.6 Therapeutic optometrists will have an enhanced understanding of the management and treatment options for corneal conditions associated with contact lens wear
- 3.1.8 Therapeutic optometrists will have an enhanced understanding of how to comply with requirements for patient consent to treatment, management or referral of corneal problems associated with contact lens wear, so they can act within their scope of practice in a multidisciplinary eyecare service team

For dispensing opticians

- 2.3.2 Dispensing opticians will have an enhanced understanding of how to comply with requirements for consent to contact lens fitting, treatment or referral of corneal problems associated with contact lens wear, so they can act in a supporting role within their scope of practice in a multidisciplinary contact lens service team
- 3.1.2 Dispensing opticians will have an enhanced understanding of the use of a slit lamp to differentiate sight-threatening microbial keratitis from less serious conditions
- 8.1.1 Dispensing opticians will have an understanding of the diagnosis and assessment of corneal problems associated with contact lens wear

For contact lens opticians

- 2.3.2 Contact lens opticians will have an enhanced understanding of how to comply with requirements for consent to contact lens fitting, treatment or referral of corneal problems associated with contact lens wear, so they can act within their scope of practice in a multidisciplinary contact lens service team
- 3.2.2 Contact lens opticians will have an enhanced understanding of use of a slit lamp for differential diagnosis of contact lens-induced peripheral ulcer and different forms of microbial keratitis
- 5.4.1 Contact lens opticians will have an understanding of the investigation and assessment of corneal sterile ulcers and different forms of microbial keratitis

The discussion tasks for the interactive learning option are as follows:

1. Discuss with your colleague the effects of contact lens-associated peripheral ulcer (CLPU).
2. Discuss with your colleague the effects of microbial keratitis (MK).
3. Discuss with your colleague the personal learning outcomes you have gained from this module and how you will apply this learning to practice. Consider the following questions (you will upload these reflections to iLearn and to myGOC within 30 days of completing the quiz).
 - 3.1. What are the main things you learned from the reading?
 - 3.2. How will you apply this learning in your future practice?
 - 3.3. Has this module identified for you any areas in which you wish to pursue further learning?